

Histomorphological and Biochemical Studies On The Ameliorative Effects Of Ethanol Root Extract of *Mucuna pruriens* on Lead-Induced Renal Toxicity In Adult Wistar Rats.

Atuadu VO¹, Finbarrs-Bello E¹, Esom EA¹, Neboh EE³, Mba CE¹, Egwuatu IA¹, Abire IE¹, Ocho PC¹

¹Department of Anatomy, Faculty of Basic Medical Sciences, College of Medicine, Enugu State University of Science and Technology (ESUT), Enugu State, Nigeria.

³Department of Medical Biochemistry, Faculty of Basic Medical Sciences, College of Medicine, Enugu State University of Science and Technology (ESUT), Enugu State, Nigeria.

*Author for Correspondence: vivianatuadu@gmail.com

ABSTRACT

Lead poisoning has been implicated as one of the causes of renal impairment. This study explores the ability of Ethanol root extract of *Mucuna pruriens* (EREMP) to attenuate the effect of lead poisoning on the kidney. Thirty-five female Wistar rats (180g), of 12 months old were divided into 7 groups (A-G) (n=5). Group A received normal saline, Group-B was exposed to lead poisoning; 120 mg/kg body weight of lead-acetate. C-D received (100 and 200) mg/kg body weight of EREMP only; the rationale was to observe the sole effect of the extract. Groups E and F animals were exposed to lead poisoning (120 mg/kg bw of lead acetate) simultaneously with 100 and 200 mg/kg bw respectively of EREMP. Group G received 120 mg/kg-bw of lead-acetate simultaneously with Vitamin E. All treatments were given orally and lasted for 21 days. The animals were sacrificed by cervical dislocation 24 hours after the last administration. Blood was collected for renal function tests while the kidney was harvested and processed for routine H & E staining. *Mucuna pruriens* root extract significantly reduced the urea and creatinine levels of rats in the treatment groups (E-F) compared to group B (p<0.05). The histological sections of the kidney of rats in group B (lead-acetate only) showed marked widespread renal tubular necrosis with mononuclear leukocytic infiltration of the renal interstitium when compared with groups E-F and group G treated with Vit E (100mg/kg-bw). Ethanol root extract of *Mucuna pruriens* can be successfully applied to the management of renal dysfunction.

Key words: *Mucuna pruriens*, blood urea nitrogen (BUN), creatinine,

INTRODUCTION

Kidney diseases are considered a public health issue worldwide as they contribute to approximately 850,000 deaths each year, making them the 12th leading cause of death (Nasri, 2014; Schieppati and Remuzzi, 2005). This is because humans are both intentionally and unintentionally exposed to a variety of diverse chemicals (drugs, natural products, poisons, toxins, industrial chemicals, environmental pollutants like lead) that harm the kidney (Rick and Katrina, 1997). Lead toxicity is probably the commonest form of heavy metal intoxication as its continuous environmental and occupational exposure may contribute to renal, nervous, hepatic, hematological and reproductive disorders in man and animals (Flora et al., 2006; Ashry et al., 2010). Landrigan (1989) also made clear that the damage done by lead toxicity is dose and duration dependent. This explains that the duration of exposure to Lead metals and the

quantities being exposed to, may determine the severity of the poisoning. Probably, the route of exposure may also play an important role in the severity of intoxication being noticed in humans. The kidneys are the main excretory organ of lead so they are vulnerable to its toxic effects especially in patients who are previously exposed to lead in different occupations (Bilquis et al., 2014). Nolan and Shaikh (1992) confirmed that the kidney is the primary site for the initial accumulation of lead and the critical target organ of chronic lead exposure following oral or inhalation exposure in humans and animals.

Man has been driven over the years to depend on medicinal herbs (due to health challenges of many kinds) in search of health solutions. Plant-based drugs play very important roles in health care (Pradeep and Sudipta 2013), this is because medicinal plants are a rich source of bioactive phytochemicals or bionutrients (Mamta et al., 2013). *Mucuna pruriens* (Agbara) is one of such medicinal plants widely used. As a

popular drug in the Ayurvedic system of medicine and also in Nigeria (especially the south-eastern part), its parts are used in addressing various kinds of diseases (Lorenzetti et al., 1998; Khare, 2004; Obadoni and Ochuko, 2002). According to Pradeep and Sudipta (2013), the roots of *Mucuna pruriens* are traditionally used via decoction, for blood purification and diuretics. The roots have also been used both in ancient and modern times to treat kidney infections.

Herbal medicines are widely used and the assumption that plant remedies are free from undesirable side effects could be wrong as the products of some plants are potentially toxic and detrimental to health. There is paucity of documented literature on the side effects or the curative capacity of *Mucuna pruriens* (Agbara) root extract on the kidney of adult female wistar rats. Thus, this study aimed at investigating the effect and curative capacity of Ethanolic root extract of *Mucuna pruriens* (Agbara) on Lead-acetate induced kidney toxicity using adult female Wistar rats.

MATERIALS AND METHODS

Plant material

Fresh roots of *Mucuna pruriens* was procured from a farm land in Obinagu, Amechi-Idodo in Nkanu-East LGA of Enugu State, South-Eastern part of Nigeria and was identified at the Faculty of Agricultural Science, Enugu State University of Science and Technology (NIH, 2011).

Processing of plant material and Extract preparation

Fresh roots of *Mucuna pruriens* were washed, the roots were cut into small pieces and shade dried for 14 days at room temperature. The dry roots were grinded into powder using an electronic grinder. Ethanol extraction of plant material was done according to the methods of Nwifo et al., (2017). The extract was transferred to an airtight bottle and stored in a refrigerator at 4°C prior to use.

Experimental animals

Thirty (30) nulliparous and non-pregnant healthy adult female wistar rats (180 g) were

purchased from the animal house of the Enugu State University of Science and Technology College of Medicine, Parklane, Enugu and were bred in the Animal facility of the animal house. The animals were housed in netted iron cages and were provided easy access to food (growers mesh) and water *ad libitum*. The animals were maintained under standard laboratory conditions (Temperature 24°C ± 2°C, with relative humidity of 60-70% under 12 hours light and dark cycles) and were allowed to acclimatize for two weeks prior to the experiment. Animals were cared for in accordance with the standard and guidelines of the National Institute of Health for care and use of laboratory animals.

Experimental design and animal grouping

Thirty-five female Wistar rats (180g), of 12 months old were divided into 7 groups (A-G) (n=5). Group A was given normal saline. Group-B was exposed to lead poisoning; by administering 120 mg/kg body weight of lead-acetate. C-D received (100 and 200) mg/kg body weight of EREMP only; the rationale was to observe the sole effect of the extract. Groups E and F animals were exposed to lead poisoning (120 mg/kg bw of lead acetate) simultaneously with 100 and 200 mg/kg bw respectively of EREMP. Group G received 120 mg/kg-bw of lead-acetate simultaneously with 100mg/kg-bw of Vitamin E. All administrations were done orally and treatment lasted 21 days. Blood was collected with the use of capillary tube through the retro-orbital plexus for biochemical analysis. The animals were sacrificed by cervical dislocation, the kidney was harvested and processed for routine H & E staining.

Body weight Measurement

The weights of the individual rats in each group were monitored after every 7 days of the treatment using an electronic weighing balance. Percentage increase of their weekly body weights were calculated and recorded.

Blood sample Collection

Blood samples were collected by the use of capillary tube through the retro-orbital puncture. Serum were separated after centrifugation at

10,000rpm for 10 minutes and analyzed for creatinine and blood urea nitrogen. Kits used for the biochemical analysis of serum creatinine and blood urea nitrogen was the Randox® kit (**Randox Laboratories Ltd**, 55 Diamond road, Crumlin, County Antrim, BT29 4QY, United Kingdom) which was supplied by a registered laboratory.

Organ Sample Collection

At the end of the experimental period, each rat was weighed. The left kidney was then removed. The freshly harvested kidneys were rinsed with normal saline, blotted dry and weighed with an electronic weighing scale. Finally, the relative kidney weight was calculated by dividing left kidney weight by body weight and then multiplying it by 100.

$$\text{Relative organ percentage (\%)} = \frac{\text{Organ weight (left kidney) (g)}}{\text{Body weight (g)}} \times 100\%$$

Body weight (%)

The freshly harvested kidneys were fixed afterwards in a freshly prepared 10% formal saline solution in duly labeled, plastic containers, well covered for three (3) days and afterwards was processed using standard histology tissue processing protocols. The photomicrographs of the prepared slides were taken using a Motic™ 5.0 megapixels microscope camera at x400 magnification.

Statistical analysis

Data obtained from serum analysis and the relative organ percentage values were statistically analyzed using one-way analysis of variance (ANOVA). The results were expressed as mean ± standard deviation (mean ± SD), using statistical package for social science, version 23 (SPSS v23). The difference of the means was considered significant at $p < 0.05$.

RESULTS

Histological Analysis

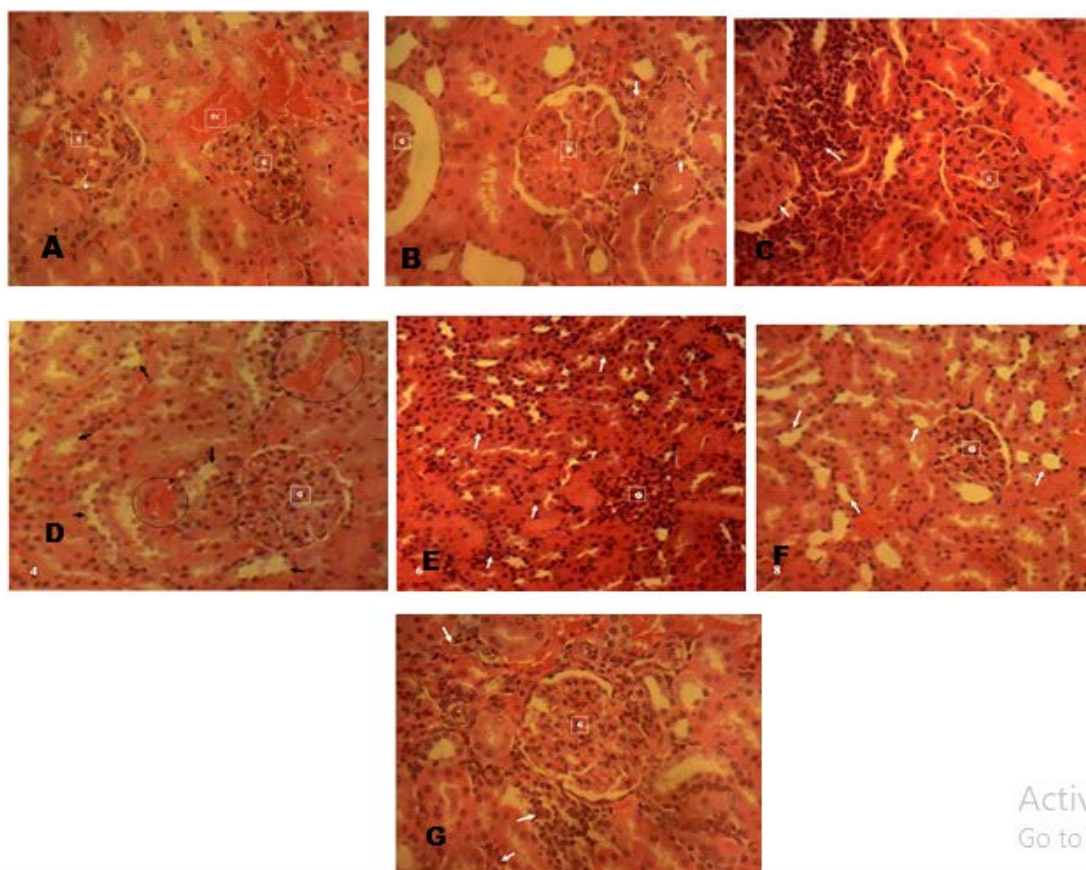


FIG 1: Photomicrograph of Kidney section of different groups

Group A: Photomicrograph of Kidney section of control animal group administered only normal saline shows the normal renal histo-architecture. Normal Glomeruli (G) in their Bowman's capsules (**white arrow**) surrounded by numerous renal tubules (**black arrow**) in the cortex and outer medullar were observed. The renal tubules are lined by ciliated simple columnar epithelia. Blood vessels (BV).

Group B: Photomicrograph of Kidney section of group B, administered with 120mg/kg-Bwt of Lead-Acetate showing a mild multifocal renal tubular necrosis with mononuclear leucocytic infiltration of the renal interstitium (arrow). Glomeruli (G). (**H & E stain x 400**).

Group C: Photomicrograph of Kidney section of animal group administered with low dose f Extract (100mg/Kg-Bwt) showing localized areas of tubular necrosis with marked localized infiltration of the renal interstitium with mononuclear leucocytes (arrow). Glomeruli (G).

Group D: Photomicrograph of Kidney section of animal group administered with high dose of Extract (200mg/Kg-Bwt) showing the normal renal histo-architecture. Glomeruli (G); Renal tubules (arrow). Also seen are areas of mild capillary congestion (circled) (**H & E stain x 400**).

Group E: Photomicrograph of Kidney section of animal group administered with 120mg/kg-Bwt of Lead-Acetate and low dose of Extract (100mg/Kg-Bwt) showing the renal histo-architecture for a laboratory rodent with a widespread infiltration of mononuclear leucocytes in the renal interstitium (arrow) and a congested glomeruli (G).

Group F: Photomicrograph of Kidney section of animal group administered with 120mg/kg-Bwt of Lead-Acetate and high dose of Extract (200mg/Kg-Bwt) showing the normal renal histo-architecture for laboratory rodents. Renal tubules (arrow), Glomeruli (G).

Group G: Photomicrograph of Kidney section of animal group administered with 120mg/kg-Bwt of Lead-Acetate and 100mg/kg-Bwt of Vit E showing a marked widespread renal tubular necrosis with mononuclear leucocytic infiltration of the renal interstitium (arrow). Glomeruli (G). (**H & E stain x 400**).

Biochemical Analysis

The positive control group (group B) induced with renal toxicity did not show any significant increase in the serum levels of creatinine but showed a significant increase ($p < 0.05$) in the levels of blood urea nitrogen when compared to the negative control group (group A) as seen in table 1. Treatment with increasing doses of the EREMP (groups E-F) after induction of renal toxicity with lead-acetate, showed a further significant ($p < 0.05$) increase in the serum levels of creatinine when compared to the negative control group (group A). Group G animals which were treated with vitamin E as a standard drug after induction of renal toxicity with lead-acetate also had a significantly increased level ($p < 0.05$) of serum creatinine when compared to the negative control group (group A) and a significant decrease ($p < 0.01$) in the levels of blood urea nitrogen when compared to the positive control group (group B).

Table 1: Results of the effect of ethanolic root extract *Mucuna pruriens* on serum creatinine concentration (SCC) and Blood urea nitrogen (BUN) levels

Groups And Treatment	SCC (mg/dl)	BUN (mg/dl)
	Mean ± Standard Deviation	Mean ± Standard Deviation
A Normal saline	1.48±0.031	^{aa} 2.67±0.18
B Lead Acetate	1.46±0.12	^{aa} 5.42±0.92**
C Extract (Low dose)	1.74±0.42	^{aa} 2.82±0.73

D Extract (High dose)	1.88±0.42	^{aa} 2.53±1.12
E Lead acetate + Extract (Low dose).	^{aa} 2.94±0.84**	^{aa} 2.24±0.39
F Lead acetate + Extract (High dose).	2.03±0.18	^{aa} 2.83±0.11
G Lead acetate + Vit E	^a 2.45±0.34*	^{aa} 2.85±0.3

“KEYS: *= $P < 0.05$, **= $P < 0.01$, ***= $P < 0.001$ when compared with group A (Normal control).
^a= $P < 0.05$, ^{aa}= $P < 0.01$, ^{aaa}= $P < 0.001$ when compared with group B (Lead acetate)”.

Body weight Analysis

The percentage change in body weights (CIBW) of the experimental animals during the period of the experiment were calculated and shown in Table 2. The group B rats administered with 120mg/kg of LA experienced a remarkable slowdown in the growth that led to obvious decrease in their body weight. Groups E, F and G

also treated simultaneously with 120mg/kg of LA and increasing doses of the EREMP, did not show much decrease in weight gain as seen in the lead acetate group. However, after the first week of treatment, these groups (E, F and G) had a slowdown in their growth. Their weight markedly increased towards the end of the experiment at the second week of treatment.

Table 2: A record of the percentage change in body weights of the experimental animals during the period of the experiment

Treatment	Week 1	Week 2	Week 3
A Normal saline	175.30±0.4	181.19±0.5	189.11±1.7
B Lead Acetate	183.00±0.06	174.56±1.5	167.17±0.8
C Extract (Low dose)	178.11±1.4	184.12±1.6	181.18±0.4
D Extract (High dose)	175.29±1.6	180.74±0.9	189.56±0.8
E Lead acetate + Extract (Low dose).	184.46±0.6	180.48±0.7	170.13±1.4
F Lead acetate + Extract (High dose).	184.54±0.3	182.04±0.1	188.2±0.5
G Lead acetate + Vit E	185.7±0.5	191.21±0.1	190.07±1.9

Organ weight Analysis

The relative organ percentages (%) of the kidneys were determined and the results were presented in Table 4.4 below. As revealed by the table, the positive control group (group 5)

induced with renal toxicity with 120mg/kg-bwt of Lead-Acetate experienced a significant increase ($p < 0.001$) in their relative kidney weight percentages when compared with the negative control. Group 2, 3 and 4 administered

with increasing doses of the Ethanolic root extract of *Mucuna pruriens* only, showed an increase in their relative kidney weight percentages when compared with the negative control. Although, their values were not statistically significant. Meanwhile, group 6, 7 8 and 9 treated with increasing doses of the Ethanolic root extract of *Mucuna pruriens* (6, 7

and 8) and Vitamin E (9) after Lead-Acetate administration also showed significant increases ($p < 0.01$ and $p < 0.05$) in their relative kidney weight percentages when compared with the negative control. These groups also showed significant decreases ($p < 0.05$ and $p < 0.001$) in their relative kidney weight percentages when compared with the positive control.

Table 3: Results of the effect of *Mucuna pruriens* ethanolic root extract on the relative organ percentages (%)

Groups And Treatment	Mean (%) ± Standard Deviation	P-Values against Negative control	P-Values against Positive control
A Normal saline	0.66±0.023	0.000204	0.000
B Lead Acetate	0.87±0.055***	0.000	0.000204
C Extract (Low dose)	^{aaa} 0.7±0.011	0.298	0.000
D Extract (High dose)	^{aaa} 0.72±0.06	0.101	0.000398
E Lead acetate + Extract (Low dose).	^{aaa} 0.73±0.055*	0.0434	0.000619
F Lead acetate + Extract (High dose).	^a 0.79±0.077**	0.00107	0.02752
G Lead acetate + Vit E	^a 0.79±0.042**	0.00128	0.023533

KEYS: * = P < 0.05, ** = P < 0.01, * = P < 0.001 when compared with group 1. a = P < 0.05, aa = P < 0.01, aaa = P < 0.001 when compared with group 5.**

DISCUSSION

The EREMP had a nephroprotective potential on the histology of the kidney when administered with Lead acetate. The lead intoxicated group B showed mild and localized areas of tubular necrosis with marked localized infiltration of the renal interstitium with mononuclear leucocytes and areas of mild capillary congestion as seen in Group B. These damages noticed is suggested to be due to the nephrotoxic effects of lead-acetate administered to the group and agrees to previous studies by Abdel-Moniem et al., (2011); Aziz et al., (2012) and Al-Attar, (2011) on the nephrotoxic effects of lead-acetate. However, the extract had a therapeutic effect as it restored the normal

histoarchitecture of the kidney tissue by reversing the signs of nephrotoxicity brought about by Lead-acetate administration. A more therapeutic effect was noticed in the high dose. The plant extract was more efficacious than the Vitamin E treated group (group G) which still showed signs of nephrotoxicity. Malek et al., (2010) classified vitamin E as a strong antioxidant but stated that its efficacy depends on the used dosage of vitamin E and the time length of administration.

The estimation of serum creatinine is a most reliable test of kidney functionality (Rajanandh, 2018). The biochemical result showed that animals in groups administered with increasing doses of the extract only (C-D), showed that the extract increased the serum

levels of creatinine and the levels of blood urea nitrogen; though not significant. Previous studies have noted that natural plant extract could cause an increase in serum levels of creatinine and blood urea nitrogen indicating their nephrotoxic potencies. Studies carried out by Mervat et al., (2012) and Muhammad et al., (2011) stated that administration of lead-acetate significantly increased the serum levels of creatinine and blood urea nitrogen indicating nephrotoxicity and renal impairment. Treatment with EREMP (group E-F) simultaneously with lead-acetate, showed a further increase in the serum levels of creatinine which was significant ($p < 0.05$ when compared to the negative control group (group A) but showed a significant decrease ($p < 0.01$) in the levels of blood urea nitrogen when compared to the lead acetate group (group B). Animals in group G treated with vitamin E simultaneously with lead-acetate also had a significantly increased level ($p < 0.05$) of serum creatinine when compared to the normal control group (group A) and a significant decrease ($p < 0.01$) in the levels of blood urea nitrogen when compared to the lead acetate group F. The significant increase in serum creatinine levels in the low dose treated groups indicates that the low dose was not sufficient to bring about a cure in the nephrotoxic damages while the decrease in blood urea nitrogen levels in all the treated groups suggested that these animal groups were still recovering from renal impairment.

Kidney size bears a relation to the degree of renal diseases (Chandra, 2013). Administration with increasing doses of the root extract only (Group B-D), showed an increase in their relative kidney weight percentages indicating kidney toxicity and confirmed by their histological sections showing nephrotoxic damages ranging from mild to moderate distortions. Obvious increases in the kidney weight of lead-acetate intoxicated animals have been documented. This detected increase in the weight or ratio of the kidney under the effect of Lead (Pb) might be because of necrosis and apoptosis which were accompanied by the accumulation of lipids in the organs (Alwaleedi, 2016). The lead intoxicated (group B) experienced a significant increase ($p < 0.001$) in their relative kidney weight percentages. In the treated animal groups (group 6, 7, 8), the EREMP

had the capacity to reduce the effect caused by lead-acetate on the kidney weight but were not sufficient to restore the normal weight range. This may be due to its potency of also causing an increase in the relative kidney weight percentage of the animals as seen in the extract-only groups.

CONCLUSION

The assumption that plant remedies are free from undesirable side effects can be wrong sometimes and the side effects can be detrimental to health; a product of some plants being potentially toxic. Therefore, medicinal plants and their bioactive molecules are always in demand and have been a central point of research over the years. The ethanolic root extract of *Mucuna pruriens* showed therapeutic effects in lead plus EREMP treated groups. Therefore, the extract is a promising agent for the cure of kidney toxicity however; caution should be paid to the consumption of this plant as it could also be of health risks.

REFERENCES

- Abdel-Moneim AE, Dkhal MA, Al-Quraishy S. (2011). The protective effect of flaxseed oil on lead acetate-induced renal toxicity in rats. *J. Hazard Mater.* 30 (194): 250-5.
- Al-Attar MA. (2011). Antioxidant effect of vitamin E treatment on some heavy metals-induced renal and testicular injuries in male mice. *Saudi J. Biol. Sci.*, 18: 63-72.
- Alwaleedi SA. (2016). Hematobiochemical changes induced by lead intoxication in male and female albino mice. *National Journal of Physiology, Pharmacy and Pharmacology.*, 6(1); 46-51.
- Ashry KM, El-Sayed YS, Khamiss RM, El-Ashmawy IM. (2010). Oxidative stress and immunotoxic effects of lead and their amelioration with myrrh (*Commiphora molmol*) emulsion. *Food Chem Toxicol*; 48(1):236-41.
- Aziz FM, Maulood IM, Chawsheen MAH. (2012). Effects of melatonin, vitamin C and E alone or in combination on lead-induced injury in liver and kidney organs of rats. *IOSR J. Pharmacy*, 2(5): 13-18.
- Begum B, Rana IN, Mudassar M. (2014). Lead induced Morphological Changes in the Kidneys of Albino

- Mice. Journal of Rawalpindi Medical College (JRMC); 18(1):75-79
- Chandra P, Deopa D, Thakkar HK. (2013). Study of Internal Organ Weight and Its Correlation to Body Weight in Kumaon Region of Uttarakhand. J Indian Acad Forensic Med. Jan-March 2013, Vol. 35, No. 1: 29-32.
- Flora S, Flora G, Saxena G. (2006). Environmental occurrence, health effects and management of lead poisoning. In: Casas JS, Sordo J, editors. Lead: chemistry, analytical aspects, environmental impact and health effects. Amsterdam, Netherlands: Elsevier Science; 158-228.
- Khare CP. (2004). Encyclopedia of Indian medicinal plants. Springer verley Berlin Heidelberg.
- Landrigan PJ. (1989). The toxicity of lead at low dose. Br J Ind Med.; 46:593-96.
- Lorenzetti E, MacIsaac S, Arnason JT, Awang DVC, Buckles D. (1998). The phytochemistry, toxicology and food potential of velvet bean (*Mucuna Adans spp.*, Fabaceae) Cover crops of West Africa: contributing to sustainable agriculture. IDRC, Ottawa, Canada & IITA, Ibadan, Nigeria; 57.
- Mehranjani MS, Noorafshan A, Hamta A, Reza H, Abnosi MH, Mahmoodi M, Anvari M, Hazaveh M. (2010). Effects of vitamin E on ovarian tissue of rats following treatment with p-nonylphenol: A stereological study. Iranian Journal of Reproductive Medicine., 8(1): 1-9,
- Ghoniem MH, El-Sharkawy NI, Hussein MMA, Moustafa GG. (2012). Efficacy of Curcumin on Lead Induced- Nephrotoxicity in Female Albino Rats. Journal of American Science; 8(6): 502-510.
- Suleman M, Khan AA, Hussain Z, Zia MA, Roomi S, Rashid F, Iqbal A, Ishaq R, (2011). Effect of lead acetate administered orally at different dosage levels in broiler chicks. African Journal of Environmental Science and Technology. 5(12); 1017-1026
- Muhammad YB, Adam AA, Jamil DU, Lukman OA, Opke J. (2015). M. Effect of aqueous extract of *Mucuna Pruriens* leaves on liver and kidney function markers in wister albino rats. American Journal of Innovative Research and Applied Sciences; 1(10):379-383.
- Nasri H. (2014). World kidney day. Chronic kidney disease and aging: A global health alert. Iran. J. Public Health, 43, 126-127.
- Nolan CV, Shaikh ZA. (1992). Lead nephrotoxicity and associated disorders: biochemical mechanisms. Toxicology, 73:127-146.
- Nwifo C, Ene C, Emejulu A, Obasi K, Ene U. (2017). Antidiabetic Properties of Ethanolic Root Extract of *Mucuna Pruriens* on Alloxan Induced Diabetic Rats. International Journal of Research in Pharmacy and Biosciences. 4(5);17-29.
- Obadoni BO, Ochuko PO. (2002). Phytochemical studies and comparative efficacy of the crude extracts of some haemostatic plants in Edo and Delta States of Nigeria. Global Journal of Pure and Applied Sciences. 8(2), 203-208.
- Kumar P, Saha S. (2013). An updated review on Taxonomy, Phytochemistry, Pharmacology and Toxicology of *Mucuna pruriens*. Journal of Pharmacognosy and Phytochemistry. Vol. 2(1); 306-312.
- Rajanandh MD. (2018). Renal Function Tests. [Online] Available at: www.srmuniv.ac.in Date accessed: 2/06/2018
- Schnellmann RG, Kelly KJ, (1997). Chapter 15; Pathophysiology of Nephrotoxic Acute Renal Failure. In Diseases of the Kidney. Edited by Schrier RW, Gottschalk CW. Boston: Little Brown.
- Schieppati A, Remuzzi G. (2005). Chronic renal diseases as a public health problem: Epidemiology, social, and economic implications. Kidney Int. Suppl.