

PROTECTIVE EFFECT OF CURCUMIN ON LINDANE-INDUCED HEPATOTOXICITY IN MALE WISTAR RATS

Yadav N.¹, Kumar H.² Chandra S^{3*}

¹Department of Zoology, Institute of Basic Sciences, Bundelkhand University, Kanpur Road, Jhansi- 284128, India

²Department of Pathology, S.N. Medical College, Agra-282002, U.P., India

³Department of Zoology, Charak Institute of Education, IIM Road, Maura, Lucknow-226 020, U.P., India.

***Author for Correspondence:**

satishchandra.lu@gmail.com; dr.neelamyadav23@gmail.com

ABSTRACT

Lindane (C₆H₆Cl₆) an organochlorine pesticide has been used in agriculture and domestic purposes for several years. The aim of present study was to analyze the oxidative effect of lindane which caused biochemical and ultrastructural changes in adult male wistar rats and to evaluate the possible protective effect of Curcumin (C₂₁H₂₀O₆). Tissues damage was assessed by histopathological observation. Curcumin plays an important role as an antioxidant and consequently expected to protect tissues from damage caused by reactive oxygen metabolites. Rats were divided into seven groups. Group-A, was given normal diet and water ad libitum. Lindane (30 mg/kg body weight) was administered orally for 14 and 28 days in group- B and group-C respectively. Curcumin (100 mg/kg body weight) was given to Group-D and Group-E. Lindane (30 mg/kg body weight) along with Curcumin (100 mg/kg body weight) was administered orally for 28 days in group-F. Group-G, was allowed to metabolize after 14 days of exposure to lindane. Lindane administration lead to a significantly (P<0.001) increase in hepatic lipid peroxidation (LPO) associated with reduction in levels of GSH (Glutathion), activity of SOD (Super Oxide Dismutase), CAT (Catalase) and GST (Glutathione-S-transferase). Pre-feeding and post-feeding of Curcumin resulted in decreased hepatic levels of lipid peroxides (LPO) and increased GSH (C₁₀H₁₇N₃O₆S), SOD, CAT (Catalase) and GST (Glutathione-S-transferase) activities. Results revealed that Curcumin in combination with lindane partially or totally alleviated its toxic effects on the studied parameters. In conclusion, Curcumin have beneficial effects and could be able to antagonize lindane toxicity.

Keywords: Curcumin, Lindane, Hepatic, Wistar Rats.

INTRODUCTION

Lindane, a γ -isomer of Hexachlorocyclohexane organochlorine pesticide and is widely spread in the environment due to its long lifetime (Wauchope et al. 1992). Pesticide extensively employed for public health and agricultural purposes in developing countries. Because of its widespread use, lindane has become widely distributed in ecosystem and now a global pollutant. Several studies have revealed the presence of lindane above permissible limit in body fat, blood, milk and food commodities both in India and abroad (Samanta et al. 1999). It has been used widely as therapeutic Scabicide, Pediculicide and ectoparasiticide (Fidan et al. 2008). Presently, lindane also used in lotions, creams and shampoos for the control of lice and mites in humans (Safe, 1993). Compounds of this chemical class have very low water solubility

but are highly soluble in lipids and bioaccumulated (Murphy, 1986). Toxic effects of lindane in mammals include convulsions, ataxia, prostration, damage to fatty tissues and inhibition of sperm motility in sea urchins (Nelson, 1990). It has been reported to induce oxidative stress by interacting with the cell membrane, triggering the generation of reactive oxygen species (ROS) and altering the level of antioxidant molecules which in turn cause severe physiological dysfunction in various organ systems (Bano and Bhatt, 2007). Recent studies indicate that pesticide intoxication produce oxidative stress by the generation of free radicals (Banerjee, 1999) and induce tissue lipid peroxidation (LPO) (Yavuz, 2005). ROS (Reactive oxygen species) arise as by-products of normal cellular metabolism or may be the consequence of exposure to certain chemicals (Kerr et al. 1996) and responsible for structural

and functional alterations in cells (Fernandez et al. 2003). Normal cellular functions depend on a balance between ROS (Reactive oxygen species) produced and antioxidant defense mechanisms present in the cell.

In search for these new chemical entities as modulators of xenobiotic metabolism, we searched literature on Ayurvedic medicinal plants. Several medicinal plants or their active principles have been used as antioxidants and in reducing the toxicity of xenobiotics. However, it based on the experience of traditional system of medicine from different ethnic societies. The medicinal plant *Curcuma longa* (Turmeric) has attracted the interest of research community due to its number of pharmacological activities (Srimal, 1997). Curcumin, an active component of turmeric (*Curcuma longa* linn) exhibits an antioxidant property. It is a yellow coloured phenolic pigment yield from the rhizome of turmeric (Family: Zingiberaceae). Earlier studies have shown that it is an effective antioxidant against oxidative tissue damage and inhibits ROS (Reactive oxygen species) production (Quiles et al. 2002) both, also acts as a scavenger of free radicals (Khanna, 1999). Therefore, the present study has been undertaken to evaluate the ameliorating effect of Curcumin on lindane induced biochemical and histopathological alterations in hepatic tissues of rat.

MATERIALS AND METHODS

Chemicals

Pure lindane 99.6% and Curcumin were purchased from Sigma Aldrich (St. Louis, Mo. USA). All other chemicals were of AR grade and purchased locally.

Experimental design

Forty-two male wistar rats (Weighing 130–150 g) were obtained from the animal house of the IITR (Industrial Institute of Toxicology Research). Animals were caged in seven groups (Each group having six rats) and given food & water *ad libitum*. The animal room was maintained at 21–24 °C and 40–60% relative humidity with 12-h light–dark cycles, the light cycle coinciding with the day light hours. After 2 weeks of acclimation, the groups were assigned at random to one of the following treatments: group A served as control, while groups B and C

were treated with 30 mg lindane/kg body weight, up to 14 and 28 days respectively. Group D received Curcumin 100 mg/kg body weight up to 14 days than received lindane 30 mg/kg body weight up to next 14 days. Group E was given lindane 30 mg/kg body weight up to 14 days than received Curcumin 100 mg/kg body weight up to next 14 days. While group F was given lindane (30 mg/kg body weight) plus Curcumin (100 mg/kg body weight). The animal G received lindane 30 mg/kg body weight up to 14 days and then were kept for metabolism up to next 14 days. The dose of LD50 (Lethal Dose) (lindane), when administered orally to rats has been reported to be given at the rate of 88 mg/kg body weight (Gaines, 1959). Animals were treated orally with the tested compounds every other day for 28 days. The doses of lindane and Curcumin were calculated according to the animal's body weight before treatment.

Sample collection

Rats of each group were killed by decapitation at the end of the treatment period. Samples (Liver) were collected from the sacrificed animals and placed immediately on -20°C temperature. Frozen liver samples were thawed and 200 mg of samples was weighed and taken in 2ml of ice –cold saline for enzyme estimation. An amount of 200 mg of sample was weighed separately and taken in 2 ml of 0.02 M EDTA for GSH (Glutathion) estimation. Tissue sections were taken from liver & both kidneys for histopathological examination, which were fixed in 10% formalin. Organ homogenates were prepared using tissue homogenizer (IKA, Germany) under ice-cold condition. The homogenate was centrifuged for 10 min at 3000 rpm (Revolution per minute). The supernatant was used for following biochemical estimation.

Measurement of malondialdehyde

Malondialdehyde ($C_3H_4O_2$) occurs in lipid peroxidation and was measure in liver and kidney tissues after incubation at 95°C with thiobarbituric acid in aerobic conditions (P^H 3.4). The pink colour produced by these reactions was measure spectrophotometrically at 532 nm (Nanometer) to measure MDA (Malondialdehyde) levels (Shafiq, 1984).

Specific activity was defined as nanomole per milligram protein.

Measurement of Superoxide dismutase (SOD)

SOD (Super Oxide Dismutase) estimated as per the method (Madesh and Balasubramanian, 1998). It involved generation of superoxide by pyrogallol ($C_6H_6O_3$) auto oxidation and inhibition of superoxide-dependent reduction of the tetrazolium dye MTT ($C_{18}H_{16}BrN_5S$) to its formazan (CH_4N_4), measured at 570nm. The reaction was terminated by the addition of dimethyl sulfoxide (DMSO: $C_2H_6O_s$), which helps to solublize the formazan formed. The colour evolved to stable for many hours and expressed as SOD (Super Oxide Dismutase) units (Have been expressed as U/g of protein) [One unit SOD (Super Oxide Dismutase) is amount (μ g) of protein required to inhibit the MTT reduction by 50%].

Measurement of Catalase (CAT)

Activities of Catalase in liver homogenate were estimated (Bergmeyer et al. 1983) Diluted (1:10) of homogenate was used for estimation of catalase. The optical density recorded at every 10 sec for 1 min at 240 nm (Nanometer) against water blank.

Measurement of Glutathione-S-transferase (GST)

GST activity measured by the method (Habig et al. 1974). Assay for the activity of GST based on the spectrophotometric determination of a CDNB (1-Chloro2, 4-Dinitrobenzene: $C_6H_3ClN_2O_4$) conjugate formed with glutathione in a GST coupled. The conjugate formation is GST (Glutathione-S-transferase) catalyzed and therefore is a measure of GST activity. The changes in absorbance recorded at 340 nm and the enzyme activity calculated as nmol CDNB conjugate formed /min/mg/protein using a molar extinction coefficient of $9.6 \times 10^3 M^{-1} cm^{-1}$.

Measurement of Reduced glutathione (GSH)

Reduced glutathione was determined (Jollow et al. 1974). The method described is based on the development of a yellow colour when Ellan's reagent (DTNB: $C_{14}H_8N_2O_8S_2$) is added to sulphohydril compounds. The colour develops fairly stable for 10 minutes. The reaction read at 412 nm.

Histopathological examination

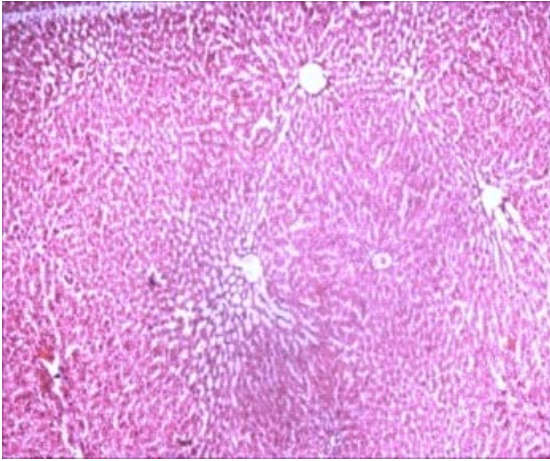
Small representative pieces (5 mm thickness) of respective organs viz., Liver collected in 10% neutral buffered formalin solution. After 3-4 days fixation, tissues were trimmed to 2 mm thickness by sharp blade. Further processing done by dehydrating the tissue in ascending grades of ethyl alcohol, clearing in xylene (C_8H_{10}), then tissue embedded into melted paraffin wax (melting point $58^{\circ} C$), after hardening of wax, tissue blocks were prepared & sections cut with microtome to obtain 4-5 μ thick sections These sections hydrated by treating with descending grades of alcohol. These tissues were double stained with hematoxyline and eosin stain. Sections treated with xylene to remove water & mounted with cover slip using DPX as mounting media. Sections examined with a NIKON (Eclips 8i) DXM 1200X light microscope (Japan).

Statistical analysis

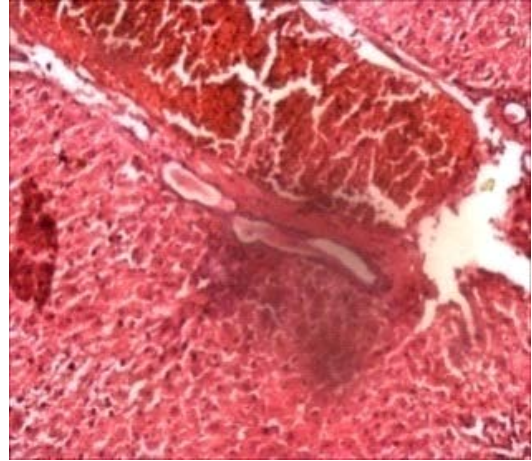
All data were analyzed via ANOVA using Graph Pad in Stat Software Inc., v. 3.06, San Digeo, USA followed by Tukey tests and the statistical significance was considered at $P < 0.05$.

RESULT AND DISCUSSION

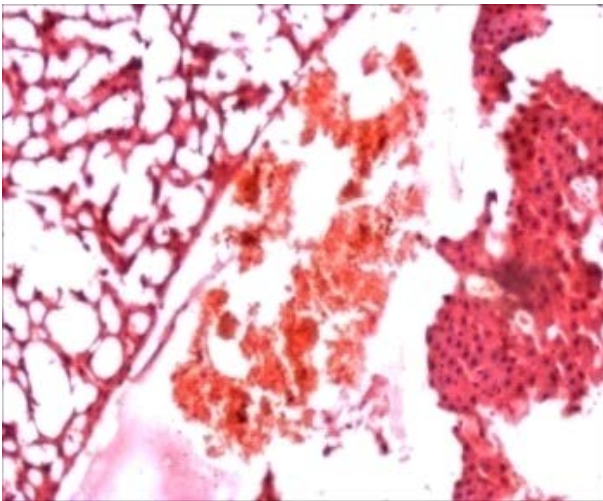
Fig. 1 demonstrated that the rats treated with lindane alone for 14 and 28 days caused extensive liver injuries characterized by vacuolar degeneration of hepatocytes and massive degradation of central vein with marked necrosis and fatty changes in parenchyma. This may occur due to periportal lymphocytic infiltrations in liver tissue mainly through the portal tract, where the inflammation mainly initiates (Ramadori et al. 2008).



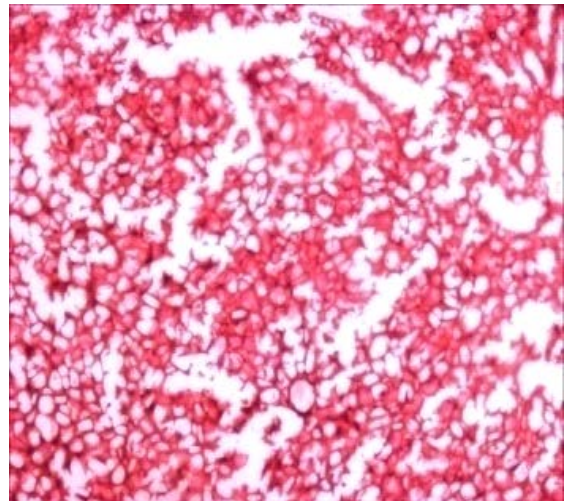
Control (a) Liver section of control rat demonstrated the normal hepatocellular structure.



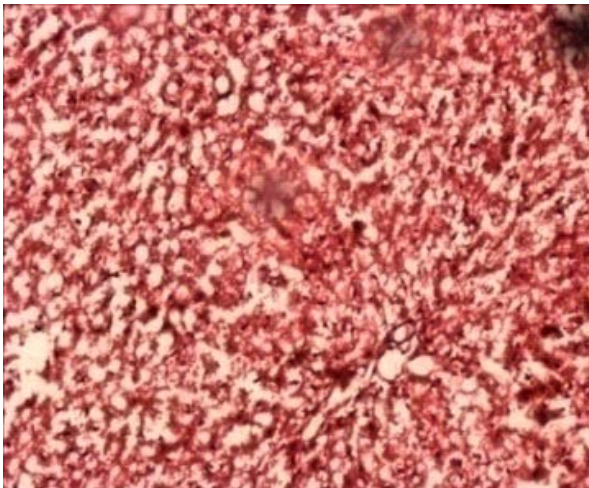
Exposure (14 days) (b) Section of the liver of lindane alone (for 14 days) treated rat showed Marked necrosis in centrilobular area



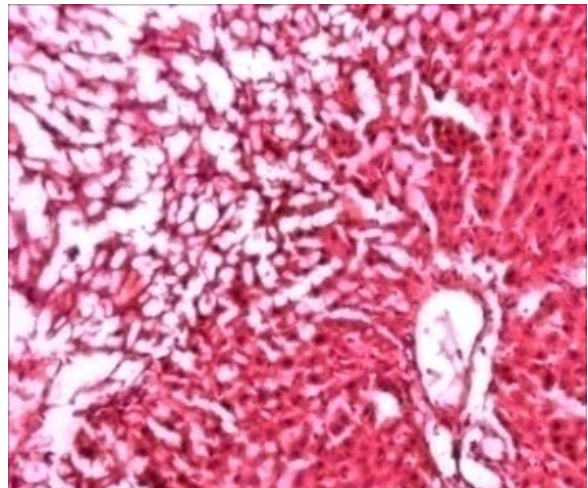
Exposure (28 days) (c) Section of the liver of lindane alone (for 28 days) treated rat showed fatty changes and degenerative changes in hepatic parenchyma



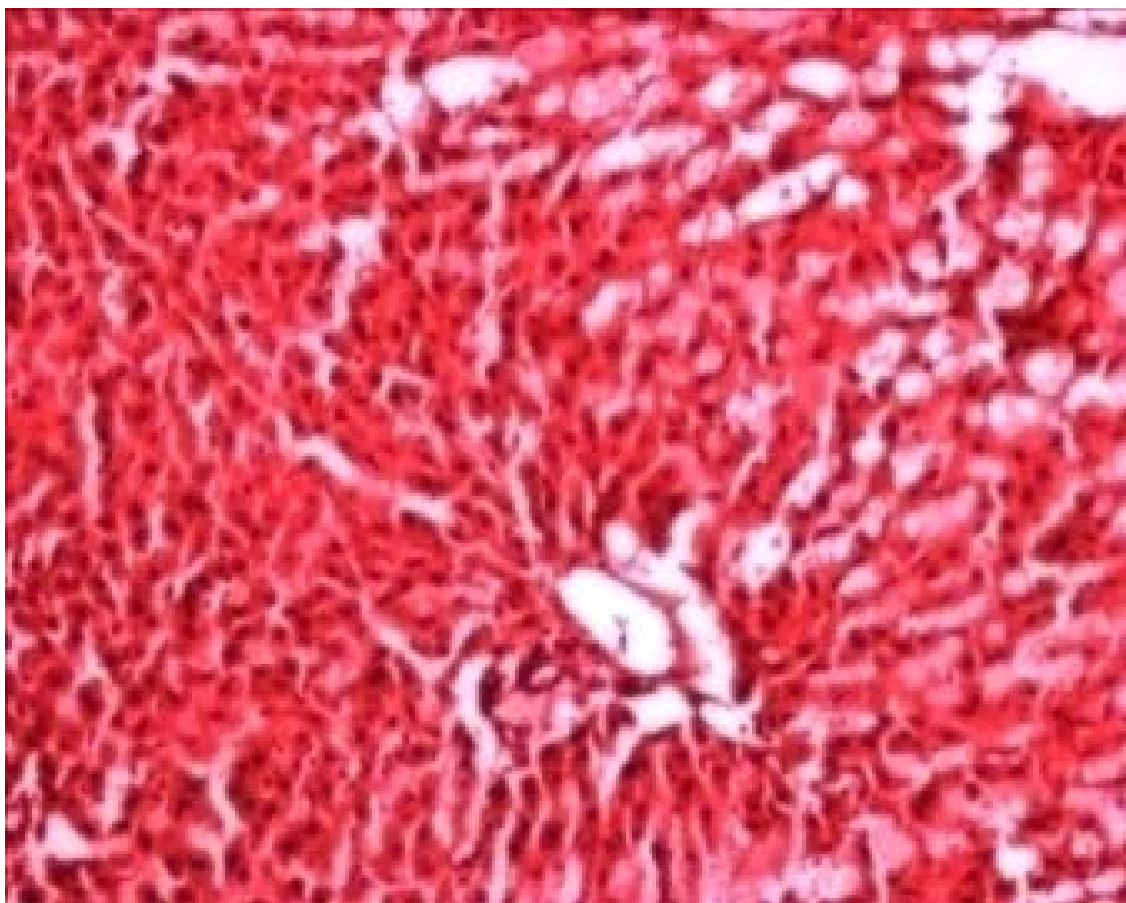
Pre-treatment (d) Hepatic section of pre-treated (with Curcumin) rat depicted congestion in central and portal veins and showing normal structure of hepatocytes



Post-treatment (e) Hepatic section of post-treated (with Curcumin) rat showing normal structure of hepatocytes with mild congestion in lumen.



Metabolized (f) Section of the liver of lindane metabolized rat Hepatocytes showing degeneration with granular cytoplasm and



Combinant (g) Section of the liver of lindane+Curcumin treated rat reverted to almost normal hepato cellular architecture

Fig.1. Histopathological examination of haematoxylin-eosin stained liver section of normal and experimental rats with magnification $\times 100$.

In addition, enhanced lipid peroxidation induced by free radicals which are generated from lindane (Padma et al. 2011), the covalent binding of free radicals, to sulphhydryl groups of protein results in cell necrosis and lipid peroxidation induced by decrease in glutathione in the liver which causes hepatocellular injury (Rajesh and Latha, 2004). In this regard, Padma et al. (2012) have documented that lindane causes centrilobular hypertrophy and necrosis in the liver. While the Control animals and pre & post-treated animals showed nearly normal hepatic architecture. However, the animals treated with both lindane and Curcumin showed reduction in liver damage with slight necrosis and fatty vacuoles in the hepatocytes with focal vascular congestion. Animals of metabolized group showed degeneration of hepatocytes with granular cytoplasm and vacuolations.

Oxidative damage primarily occurs through the production of reactive oxygen species (ROS), including hydroxyl radicals and

hydrogen peroxide that subsequently react with biological molecules, causing damage to membranes and other tissues (Banerjee et al. 1999). The present study reports that Curcumin ameliorates the lindane induced toxicity. In agreement with previous studies, we have shown that lindane induced hepatic damage in exposed to male rats (Videla et al. 1990) and that this may be due to depletion in cellular thiol (SH) levels (Mullar, 1986). Increased generation of superoxide radicals lead to oxidation and depletion of GSH (Glutathion) with a lipid peroxidative response. Glutathione, an endogenous antioxidant plays a critical role in detoxification of reactive oxygen species and free radicals.

Several studies using animal model have shown that the use of phytochemicals from plant extracts were protective against the oxidative stress induced by many toxic agents mostly by modulating the GSH (Glutathion) and GST levels (Shanmugarajan et al. 2008). GST

(Glutathione-S-transferase) catalyses the reaction between thiol (SH) group of GSH and potential alkylating agents, such as lindane, thereby neutralizing the electrophilic sites and rendering them more water soluble. This enzyme is therefore a major component of the GSH (Glutathion) redox cycle. The activity of this enzyme is a crucial factor in determining the sensitivity of cells to broaden the range of toxic chemicals. Curcumin elevates GSH (Glutathion) and GST (Glutathione-S-transferase) levels in presence or absence of lindane and this may be responsible for the protective effect of the Curcumin against lindane toxicity.

Several enzymes in hepatic tissues have considered as long effective biochemical markers to understand the early injury. Table-1 depicts the enzymatic antioxidants activities in the hepatic tissues of control and experimental rats. The present study revealed that the administration of lindane resulted in significant ($P < 0.001$) rise in hepatic lipid peroxidation (LPO). Lipid peroxidation is a free radical mediated chain reaction, which can be initiated by hydroxyl radicals and attack polyunsaturated fatty acids in membranes resulting in oxidative damage (Hfaiedh et al. 2012). Lindane exposed rat have shown marked increase lipid peroxidation in liver. It has been shown that lindane interacts with cell membranes resulting in lipid peroxidation. Lindane elevates lipid peroxidation in rat's hepatic tissue exposed to lindane toxicity and this attributed to decrease antioxidant activities (Padma et al. 2012). The rise in lipid LPO (Lipid peroxidation) level may be due to the increase in generation of the free radicals. These free radicals attack cell structure with the body causing damage to cell membrane and enzyme system. In this regard, Vijayvel et al. (2006) documented that free radical play a prominent role in elevating LPO and potentially leading to cellular damage. Induction of cytochrome P450 and other microsomal enzyme by various pesticides, e.g. carbamate, has been reported and it is possible that lindane mediated free radical generation could be through induction of these enzyme (Padma et al. 2012). Increase malondialdehyde level in tissues of animals exposed to toxic agents and this effect was attenuated by the use of various plant extracts (Guldure et al. 2010). The dietary intake of these extracts is considered to be relatively

safe and without undesirable side effects (Xavier et al. 2004).

The increase in hepatic LPO (Lipid peroxidation) content produced by lindane was significantly ($P < 0.001$) lowered by Pre and post feeding of Curcumin. The result obtained from this present study correlates with the previous findings. The study showed that the pre and post treatment of Curcumin attenuates MDA level in the presence of lindane. This reduction in MDA level may be as a result of increase GSH (Glutathion) and GST activities in the presence of Curcumin. These results are similar to the observation of another study where gallic acid shown to decrease LPO (Lipid peroxidation) level in carbon tetrachloride induced damage in albino rats (Jadon et al. 2007). Similarly, El-Dermerdash et al. (2009) have been reported that treatment with Curcumin reduced the level of LPO (Lipid peroxidation) and induced the activities of the antioxidant enzymes, the levels of SH-groups in Super Oxide Dismutaseium arsenite and haloperidol respectively.

Hepatic GSH (Glutathione) level was significantly ($P < 0.001$) reduced on lindane administration compared to control. The observed decreased GSH level in both hepatic tissue may be due to utilization of non-protein thiols by increase ROS under lindane induced oxidative stress (Bano and Bhatt, 2007). SUPER OXIDE DISMUTASE and CAT activities in hepatic tissues were decreased significantly ($P < 0.001$) in lindane exposed groups compared to control (Table-1). Superoxide dismutase (SOD) and Catalase (CAT) are two important enzymatic antioxidants that act against toxic oxygen free radicals such as superoxide (O_2^-) and hydroxyl ions (OH^-) in biological systems (Zelko et al. 2002). CAT (Catalase) prevents oxidative hazards by catalyzing the formation of H_2O and O_2 from H_2O_2 (Kumar and Kuttan, 2003). In this regard, Padma et al. (2011) have documented that lindane cause depletion in activity of CAT in liver of female Wistar rats. Similar findings were reported (Khan, 2006) after exposure of organophosphorus and pyrethroid in liver of mice. Lindane exposure usually decreases the activities of Super Oxide Dismutase and CAT (Anilakumar et al. 2009). This implies that lindane causes an increased intracellular accumulation of H_2O_2 and

superoxide radicals. The accumulation will further contribute to the membrane damage via lipid peroxidation (LPO). Present study, we have observed, a decrease in the SOD and CAT activities of the liver tissues on lindane administration. Pre and post treatment with Curcumin caused a significant increase in hepatic ($P < 0.001$) in SOD and CAT activities, suggesting an active protective role by the components present in Curcumin in ameliorating free radical- induced damage (Unnikrishnan and Rao, 1995). In agreement

with our observation Quiles et al. (2002) reported that Curcumin inhibits ROS production, which cause oxidative stress.

GST (Glutathione-S-transferase) plays an important role in the detoxification of toxic electrophiles by conjugating them with glutathione. GST is a potent antioxidant that provides cells with a substantial degree of protection against oxidative stress. Lindane significantly ($P < 0.001$) decreased GST activity in hepatic (Table-1).

Table 1: STATISTICAL REPRESENTATION OF VARIOUS PARAMETERS

Parameters	Group A	Group B	Group C	Group D	Group E	Group F	Group G
LPO	26.82±0.304	42.89±0.191***	51.42±0.287***	30.67±0.558**	31.03±0.367**	38.68±0.207**	42.70±0.386***
GST	1.26± 0.138	0.82 ± 0.007***	0.78 ± 0.007***	1.20 ± 0.055 •	1.03 ± 0.037•	0.98 ± 0.032**	0.83 ± 0.012***
GSH	30.97± 0.001	22.68±0.001***	20.12±0.001***	28.22 ± 0.002 •	26.99± 0.00**	24.45 ± 0.00**	22.90± 0.00***
CAT	78.68 ± 0.17	55.66± 1.35***	42.89±1.518***	67.86 ± 9.752**	65.99 ± 13.421**	58.22± 0.932***	56.02± 0.856***
SOD	5.12 ± 0.056	2.42 ± 0.150***	1.21 ± 0.392***	5.00 ± 0.311 •	4.99 ± 0.211 •	3.99 ± 0.188**	2.99 ± 0.233***

The decrease in GST activity might be responsible for lindane accumulation in the hepatic tissues of rat. In support of our findings Padma et al. (2011) has been reported that lindane intoxication decreases the GST level in rat liver (Spsychala, 2000), Showed a significant decrease in GST in male mice when treated with lindane. In our study, Pre and post treatment with Curcumin caused a significant increase in hepatic ($P < 0.001$) GST level in compared to lindane treated rats. This may be due to the Curcumin has been reported as potent scavenger of variety of ROS (Reddy and Reddy, 1994) exhibiting anti-inflammatory activity as well as antioxidant properties (Unnikrishnan and Rao, 1995). The phenolic and the methoxy group on the phenyl ring and the 1, 3 diketone systems seems to be important structural features that can be potent in scavenging free radicals and the phenolic group with a methoxy at the ortho position is especially effectual for the antioxidant activity (Priyadarsini, 2003).

CONCLUSION

The result of the present study demonstrate that the lindane induced oxidative

damage on the liver by enhancing lipid peroxidation and diminishing enzymatic (CAT (Catalase), GST (Glutathione-S-transferase) and SOD (Super Oxide Dismutase)) and non-enzymatic Glutathion (GSH) antioxidant status. Curcumin diminished lindane induced oxidative stress probably through its free radical scavenging, anti-lipid peroxidative and antioxidant activities in the liver. Thus, the results of our investigations suggest that Curcumin has protective effects on oxidative stress induced by lindane. Curcumin can be a potent antioxidant in the liver and kidneys. These organs are highly prone to oxidative stress against lindane induced toxicity and hence may have useful properties as a natural antioxidant supplement, capable of preventing hepatic damage caused by oxidative stress and helps in normal functioning of these vital organs.

ACKNOWLEDGMENT

Authors are thankful to Head, Department of Zoology, Institute of Basic Sciences, Bundelkhand University, Kanpur Road, Jhansi- 284128. India for providing laboratory facility. The study was part of PhD

thesis. The authors declare that there is no conflict of interest. and liver. Journal of Trace Elements in Medicine and Biology.

REFERENCES

- Anilakumar KR, Saritha V, Khanum F, Bawa AS. (2009). Ameliorative effect of ajwain extract on hexachlorocyclohexane induced lipid peroxidation in rat liver. *Food Chem Toxicol.* 47:279–82.
- Banerjee BD, Seth V, Bhattacharya A, Pauth ST, Chakraborty AK. (1999). Biochemical effects of some pesticides on lipid peroxidation and free radical scavengers. *Toxicol. Lett.* 107:33-47.
- Bano M, Bhatt DK. (2007). Neuroprotective role of a novel combination of certain antioxidants on lindane (g-HCH) induced toxicity in cerebellum mice. *Res. J. Agric. Biol. Sci.* 3:664–669.
- Bergmeyer HU, Bergmeyer J, Grassl M. (1983). Methods of enzymatic analysis / editor-in-chief, Hans Ulrich Bergmeyer, editors, Jürgen Bergmeyer and Marianne Grassl. Weinheim ; Deerfield Beach, Fla. : Verlag Chemie. 3rd ed.
- El-Demerdash FM, Yousef MI, Radwan FM. (2009). Ameliorating effect of Curcumin on sodium arsenite-induced oxidative damage and lipid peroxidation in different rat organs. *Food Chem. Toxicol.* 47: 249-54.
- Fernandez V, Massa L, Quinones KA, Giavarotti S, Almeida VD, Azzalis LA, Junqueira VB, Videla LA. (2003) Effects of gamma-hexachlorocyclohexane and L-3,30,5-triiodothyronine on rat liver cytochrome P450E1-dependent activity and content in relation to microsomal superoxide radical generation. *Biol. Res.* 36:359–365.
- Fong KL, Mecay PB, Poyer IL, Keele BB, Misra HP. (1973). Evidence that peroxidation of lysosomal membranes is initiated by hydroxyl free radicals produced during Flavin enzyme activity. *J. Biol. Chem.* 248:77–92.
- Guldur ME, Ozgonul A, Kilic IH, Sogut O, Ozaslan M. (2010). Gastroprotective effect of *Cyperus rotundus* extract against gastric mucosal injury induced by ischemia and reperfusion in rats. *Int. J. Pharmacol.* 6: 104–110.
- Habig WJH, Pabst M, Jakoby WB. (1974). Glutathione-S-transferase: The first enzymatic step in mercapturic acid formation. *J. Biol. Chem.* 249:7130-7139.
- Hfaiedh N, Claude JM, Abdelfettah E. (2012). A combination of ascorbic acid and α -tocopherol or a combination of Mg and Zn are both able to reduce the adverse effects of lindane-poisoning on rat brain
- Jadon A, Bhadauria M, Shukla S. (2007). Protective effect of Terminalia bellerica Roxb, and gallic acid against carbon tetrachloride induced damage in albino rats. *Toxicology.* 12: 165–173.
- Jollow DJ, Michell JR., Zampaglione, Gillette JR. (1974). Bromobenzene-induced Liver necrosis: Protective role of glutathione and evidence for 3, 4-Bromobenzene oxide as hepatotoxic metabolite. *Pharmacology.* 11: 151-169.
- Kerr ME, Bender CM, Monti EJ. (1996). An introduction to oxygen free radicals. *Heart Lung.* 25: 200–209.
- Khan SM. (2006). Protective effect of black tea extract on the levels of lipid peroxidation and antioxidant enzymes in liver of mice with pesticide-induced liver injury. *Cell Biochem. Funct.* 24: 327-332.
- Khanna NM. (1999). Turmeric-nature's precious gift. *Curr. Sci.* 76: 1351–1356.
- Kumar NVR, Kuttan R. (2003). Modulation of carcinogenic response and antioxidant enzymes of rats administered with 1, 2-dimethylhydrazine by picroliv. *Cancer Lett.* 191: 137–143.
- Madhesh M, Balasubramanian KA. (1998). Microtitre plate assay for superoxide dismutase using MTT reduction by superoxide. *Indian J. Biochem. Biophys.* 35:184-188.
- Mullar L. (1986). Consequence of cadmium toxicity in rat hepatocytes: Effect of cadmium on the glutathione peroxidase system. *Toxicol, Lett.* 30: 259–265.
- Murphy SD. (1986). Toxic effects of pesticides. In: Klaassen, C.D., Amdur, M.O., Doull, J. (Eds.), Casarett and Doull's Toxicology, Macmillan Publishing Co. New York, 519–581.
- Nelson L. (1990). Pesticide perturbation of sperm cell function. *Bull. Environ Contam. Toxicol.* 45: 876–882.
- Padma VV, Sowmya P, Felix TA, Baskaran R, Poornima P. (2011). Protective effect of garlic acid against lindane induced toxicity in experimental rats. *Food and Chemical Toxicology.* 49: 991–998.
- Padma VV, Lalitha G, Shirony NP, Baskaran R. (2012). Effect of quercetin against lindane induced alterations in the serum and hepatic tissue lipids in wistar rats. *Asian Pacific Journal of Tropical Biomedicine.* 910-915.
- Priyadarsini KI, Maity DK, Naik GH, Kumar MS, Unnikrishnan MK, Satav JG. (2003). Role of ns and

superoxide radicals. The accumulation will further contribute to the membrane damage via lipid peroxidation (LPO). Present study, we have observed, a decrease in the SOD and CAT activities of the liver tissues on lindane administration. Pre and post treatment with Curcumin caused a significant increase in hepatic ($P < 0.001$) in SOD and CAT activities, suggesting an active protective role by the components present in Curcumin in ameliorating free radical- induced damage (Unnikrishnan and Rao, 1995). In agreement

with our observation Quiles et al. (2002) reported that Curcumin inhibits ROS production, which cause oxidative stress.

GST (Glutathione-S-transferase) plays an important role in the detoxification of toxic electrophiles by conjugating them with glutathione. GST is a potent antioxidant that provides cells with a substantial degree of protection against oxidative stress. Lindane significantly ($P < 0.001$) decreased GST activity in hepatic (Table-1).

Table 1: STATISTICAL REPRESENTATION OF VARIOUS PARAMETERS

Parameters	Group A	Group B	Group C	Group D	Group E	Group F	Group G
LPO	26.82±0.304	42.89±0.191 ***	51.42±0.287***	30.67±0.558 **	31.03±0.367**	38.68±0.207 **	42.70±0.386 ***
GST	1.26± 0.138	0.82 ± 0.007***	0.78 ± 0.007***	1.20 ± 0.055 -	1.03 ± 0.037-	0.98 ± 0.032**	0.83 ± 0.012***
GSH	30.97± 0.001	22.68±0.001 ***	20.12±0.001***	28.22 ± 0.002 -	26.99± 0.00**	24.45 ± 0.00**	22.90± 0.00***
CAT	78.68 ± 0.17	55.66± 1.35***	42.89±1.518***	67.86 ± 9.752**	65.99 ± 13.421 **	58.22± 0.932 ***	56.02± 0.856***
SOD	5.12 ± 0.056	2.42 ± 0.150***	1.21 ±0.392***	5.00 ± 0.311 -	4.99 ± 0.211 -	3.99 ± 0.188**	2.99 ± 0.233***

The decrease in GST activity might be responsible for lindane accumulation in the hepatic tissues of rat. In support of our findings Padma et al. (2011) has been reported that lindane intoxication decreases the GST level in rat liver (Spsychala, 2000), Showed a significant decrease in GST in male mice when treated with lindane. In our study, Pre and post treatment with Curcumin caused a significant increase in hepatic ($P < 0.001$) GST level in compared to lindane treated rats. This may be due to the Curcumin has been reported as potent scavenger of variety of ROS (Reddy and Reddy, 1994) exhibiting anti-inflammatory activity as well as antioxidant properties (Unnikrishnan and Rao, 1995). The phenolic and the methoxy group on the phenyl ring and the 1, 3 diketone systems seems to be important structural features that can be potent in scavenging free radicals and the phenolic group with a methoxy at the ortho position is especially effectual for the antioxidant activity (Priyadarsini, 2003).

CONCLUSION

The result of the present study demonstrate that the lindane induced oxidative

damage on the liver by enhancing lipid peroxidation and diminishing enzymatic (CAT (Catalase), GST (Glutathione-S-transferase) and SOD (Super Oxide Dismutase)) and non-enzymatic Glutathion (GSH) antioxidant status. Curcumin diminished lindane induced oxidative stress probably through its free radical scavenging, anti-lipid peroxidative and antioxidant activities in the liver. Thus, the results of our investigations suggest that Curcumin has protective effects on oxidative stress induced by lindane. Curcumin can be a potent antioxidant in the liver and kidneys. These organs are highly prone to oxidative stress against lindane induced toxicity and hence may have useful properties as a natural antioxidant supplement, capable of preventing hepatic damage caused by oxidative stress and helps in normal functioning of these vital organs.

ACKNOWLEDGMENT

Authors are thankful to Head, Department of Zoology, Institute of Basic Sciences, Bundelkhand University, Kanpur Road, Jhansi- 284128. India for providing laboratory facility. The study was part of PhD

thesis. The authors declare that there is no conflict of interest.

REFERENCES

- Anilakumar KR, Saritha V, Khanum F, Bawa AS. (2009). Ameliorative effect of ajwain extract on hexachlorocyclohexane-induced lipid peroxidation in rat liver. *Food Chem Toxicol.* 47:279–82.
- Banerjee BD, Seth V, Bhattacharya A, Pasth ST, Chakraborty AK. (1999). Biochemical effects of some pesticides on lipid peroxidation and free radical scavengers. *Toxicol. Lett.* 107: 33-47.
- Bano M, Bhatt DK. (2007). Neuroprotective role of a novel combination of certain antioxidants on lindane (g-HCH) induced toxicity in cerebrum in mice. *Res. J. Agric. Biol. Sci.* 3: 664–669.
- Bergmeyer HU, Bergmeyer J, Grassl M. (1983). Methods of enzymatic analysis / editor-in-chief, Hans Ulrich Bergmeyer, editors, Jürgen Bergmeyer and Marianne Grassl. Weinheim ; Deerfield Beach, Fla. : Verlag Chemie. 3rd ed.
- El-Demerdash FM, Yousef MI, Radwan FM. (2009). Ameliorating effect of Curcumin on sodium arsenite-induced oxidative damage and lipid peroxidation in different rat organs. *Food Chem. Toxicol.* 47: 249-54.
- Fernandez V, Massa L, Quinones KA, Giavarotti S, Almeida VD, Azzalis LA, Junqueira VB, Videla LA. (2003) Effects of gamma-hexachlorocyclohexane and L-3,3,0,5-triiodothyronine on rat liver cytochrome P450E1-dependent activity and content in relation to microsomal superoxide radical generation. *Biol. Res.* 36: 359–365.
- Fong KL, Mecay PB, Poyer IL, Keele BB, Misra HP. (1973). Evidence that peroxidation of lysosomal membranes is initiated by hydroxyl free radicals produced during Flavin enzyme activity. *J. Biol.Chem.* 248: 77–92.
- Guldur ME, Ozgonul A, Kilic IH, Sogut O, Ozaslan M. (2010). Gastroprotective effect of *Cyperus rotundus* extract against gastric mucosal injury induced by ischemia and reperfusion in rats. *Int. J. Pharmacol.* 6: 104–110.
- Habig WJH, Pabst M, Jakoby WB. (1974). Glutathione-S-transferase: The first enzymatic step in mercapturic acid formation. *J. Biol. Chem.* 249: 7130-7139.
- Hfaiedh N, Claude JM, Abdelfettah E. (2012). A combination of ascorbic acid and α -tocopherol or a combination of Mg and Zn are both able to reduce the adverse effects of lindane-poisoning on rat brain and liver. *Journal of Trace Elements in Medicine and Biology.*
- Jadon A, Bhadauria M. Shukla S. (2007). Protective effect of *Terminalia bellerica* Roxb, and gallic acid against carbon tetrachloride induced damage in albino rats. *Toxicology.* 12: 165–173.
- Jollow DJ, Michell JR., Zampaglionic, Gillete JR. (1974). Bromoibenzene-induced Liver necrosis: Protective role of glutathione and evidence for 3, 4-Bromobenzene oxide as hepatotoxic metabolite. *Pharmacology.* 11: 151-169.
- Kerr ME, Bender CM, Monti EJ. (1996). An introduction to oxygen free radicals. *Heart Lung.* 25: 200–209.
- Khan SM. (2006). Protective effect of black tea extract on the levels of lipidperoxidation and antioxidant enzymes in liver of mice with pesticide-induced liver injury. *Cell Biochem. Funct.* 24: 327-332.
- Khanna NM. (1999). Turmeric-nature's precious gift. *Curr. Sci.* 76: 1351–1356.
- Kumar NVR, Kuttan R. (2003). Modulation of carcinogenic response and antioxidant enzymes of rats administered with 1, 2-dimethylhydrazine by picroliv. *Cancer Lett.* 191: 137–143.
- Madesh M, Balasubramanian KA. (1998). Microtitre plate assay for superoxide dismutase using MTT reduction by superoxide. *Indian J. Biochem. Biophys.* 35:184-188.
- Mullar L. (1986). Consequence of cadmium toxicity in rat hepatocytes: Effect of cadmium on the glutathione peroxidase system. *Toxicol, Lett.* 30: 259–265.
- Murphy SD. (1986). Toxic effects of pesticides. In: Klaassen, C.D., Amdur, M.O., Doull, J. (Eds.), Casarett and Doull's Toxicology, Macmillan Publishing Co. New York, 519–581.
- Nelson L. (1990). Pesticide perturbation of sperm cell function. *Bull. Environ Contam. Toxicol.* 45: 876–882.
- Padma VV, Sowmya P, Felix TA, Baskaran R, Poornima P. (2011). Protective effect of garlic acid against lindane induced toxicity in experimental rats. *Food and Chemical Toxicology.* 49: 991–998.
- Padma VV, Lalitha G, Shirony NP, Baskaran R. (2012). Effect of quercetin against lindane induced alterations in the serum and hepatic tissue lipids in wistar rats. *Asian Pacific Journal of Tropical Biomedicine.* 910-915.
- Priyadarsini KI, Maity DK, Naik GH, Kumar MS, Unnikrishnan MK, Satav JG. (2003). Role of ns and

- phenolic O-H and methylene hydrogen on the free radical reactions and antioxidant activity of Curcumin. *Free Radic Biol Med.* 35: 475–84.
- Quiles JL, Mesa MD, Ramirez-Tortosa CL, Aguilera CM, Bationo M, Gill, A. (2002). Curcuminoids as potent inhibitors of lipid peroxidation. *J Pharm Pharmacol.* 46: 1013-6.
- Ramadori G, Moriconi F, Malik I, Dudas J. (2008). Physiology and pathophysiology of liver inflammation, damage and repair. *J Physiol Pharmacol.* 59: 107-117.
- Rajesh MG, Latha MS. (2004). Preliminary evaluations of the antihepatotoxic effect of Kamilari, a polyherbal formulation. *J. Ethnopharmacol.* 91: 99-104.
- Reddy MR, Reddy GV. (1994). Utilization of sunflower (*Helianthus annuus*) plant by products in ruminant rations. In: Djajanegara A.; Sukmawati A. (Eds), Sustainable animal production and the environment. Proceedings of the 7th AAAP Animal Science Congress, Bali, Indonesia. Pp: 471-472.
- Samanta L, Sahoo A, Chainy G.B.N. (1999). Age related changes in rat testicular oxidative stress parameters by hexachlorocyclohexane. *Arch Toxicol.* 73: 96-107.
- S a f e S H . (1 9 9 3) . L i n d a n e a n d Hexachlorocyclopentadiene. *Wiley-Interscience.* 6: 135–139.
- Shafiq-Ur-Rehman. (1984). Lead-induced regional lipid peroxidation in brain. *Toxicol let.* 21(3): 333-7.
- Shanmugarajan TS, Arunsundar M, Somasundaram I, Krishna kumar E, Sivaraman D. Ravichandiran V. (2008). Cardioprotective effect of *Ficus hispida* Linn. On cyclophosphamide provoked oxidative myocardial injury in a rat model. *Int. J. Pharmacol.* 4: 78-87.
- Spychala, J. (2000). Tumor-promoting functions of adenosine. *Pharmacol. Ther.* 87: 161–173.
- Srimal RC. (1997). Turmeric: a brief review of medicinal properties. *Fitoterapia* LXVIII. 483-493.
- Unnikrishnan MK, Rao MN. (1995). Inhibition of nitrite induced oxidation of hemoglobin by Curcuminoids. *Pharmazie.* 50: 490–492.
- Videla LA, Barros SB, Janqueria VB. (1990). Lindane induced liver oxidative stress. *Free Raddic. Biol. Med.* 9: 69–179.
- Vijaya Padma V, Sowmya P, Felix TA, Baskaran R, Poornima P. (2011). Protective effect of gallic acid against lindane induced toxicity in experimental rats. *Food and Chemical Toxicology.* 49: 991–998.
- Vijayavel K, Anbuselvam C, Balasubramanian MP. (2006). Free radical scavenging activity of the marine mangrove *Rhizophora Apiculata* bark extract with reference to naphthalene induced mitochondrial dysfunction. *Chem. Biol. Interact.* 163:170-175.
- Wauchope RD, Buttler TM, Hornsby AG, Augustijn-Beckers PW, Burt JP. (1992). The SCS/ARS/CES pesticide properties database for environmental decision-making. *Rev. Environ. Contam. Toxicol.* 123: 1–155.
- Xavier R, Rekha K, Bairy KL. (2004). Health perspective of pesticide exposure and dietary management. *Malays. J. Nutr.* 10: 39–51.
- Yavuz T, Delibao N, Yaldaram B, Altuntas I, Candar O, Cora A, Karahan N, Ibrisim E, Kutsal A. (2005). Vascular wall damage in rats induced by organophosphorus insecticide ethidation, *Toxicol. Lett.* 155: 59–64.
- Zelko IN, Mariani TJ, Folz RJ. (2002). Superoxide dismutase multigene family: A comparison of the CuZn-SOD (SOD1), Mn-SOD (SOD2) and EC-SOD (SOD3) gene structures, evolution and expression. *Free Radical Med. Biol.* 33: 337-349.